

# Eye conditions in French Bulldogs

Information for breeders and pet owners

Melbourne EyeVet

Mulgrave [Essendon](#) Bundoora [Frankston](#) Geelong [Bendigo](#)

Wodonga [Traralgon](#) Darwin

The beautiful large eyes of a French Bulldog are definitely part of their appeal, however this in turn leads to an increased risk of trauma and various eye conditions. Due to the increased popularity of this happy little dog, we are seeing more visit Melbourne EyeVet with various eye diseases. Some of these conditions are minor, some require surgery, whilst others, including glaucoma that results in blindness, require intervention by the breeders to reduce the incidence. It is worth noting that breeders should educate prospective owners that if an eye is injured they need to act quickly. By seeing an eye specialist early on, expensive veterinary fees and even surgery can be avoided.



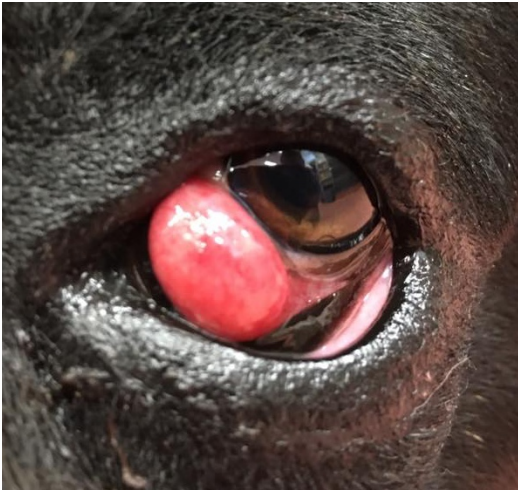
## Redness

Redness of the conjunctiva (lining of the eyeball, eyelids and third eyelid) is commonly seen in young French Bulldogs. Usually it is caused by mild allergic conjunctivitis, although some cases can progress to quite severe cases. The third eyelid (lower inner eyelid that sweeps across the eye like a windscreen wiper) is often red due to lack of pigment along the margin. In many dogs, this may affect only one eye resulting in that eye looking more red. These eyes tend to be more prone to allergic conjunctivitis.

## Dry Eye

Dry eye is a condition in which there is sub-optimal tear production. This can develop due to chronic

conjunctivitis, previous cherry eye (gland replaced or removed although much less likely if replaced), or due to immune-mediated inflammation (this is the most common form). Treatment with immuno-suppressive drugs like cyclosporin (ointment or drops) and tacrolimus are used to improve the tear readings and return the eyes to optimal health. If not treated, dry eye can result in serious corneal ulcers, scarring and vision loss.



### **Cherry Eye**

Cherry eye is a prolapse of the gland of the third eyelid. This is very common in French Bulldogs and requires surgical correction. Removal of the third eyelid gland is NOT advised as dry eye is likely. Even with surgical correction, there is still a chance that dry eye can develop, however the chance is much less. Surgical correction involves replacing the gland into a pocket on the inner surface of the third eyelid. In some cases it is necessary to also remove a portion of bent third eyelid cartilage.

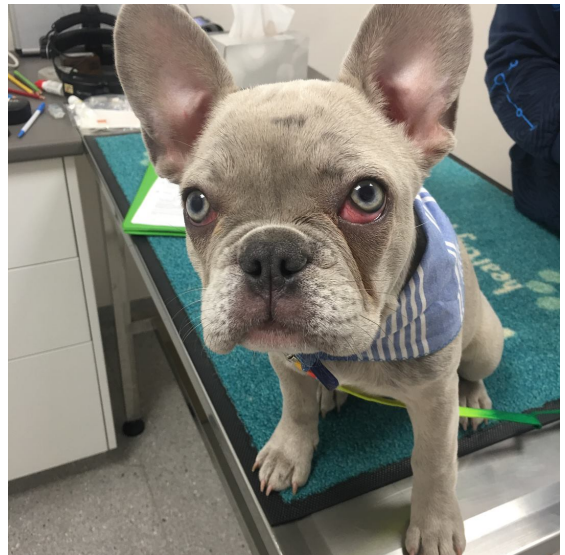
There can be swelling post op, however this usually resolves over the following days. If cherry eye develops in one eye, it is fairly likely that it will develop in the fellow eye, and so at Melbourne EyeVet we usually offer the option of doing both eyes at the same time. Always let the breeder know if cherry eye develops.

### **Extra eyelashes/distichiasis**

Distichia are abnormal extra eyelashes that grow from the glands on the eyelid edge. In some dogs they are fine and float in the tear film and don't cause problems. Other distichia are thicker and can cause irritation and corneal ulcers. Surgery is necessary in such cases to either cut them out by the root or freeze the root to destroy it. This surgery is a specialist procedure. If your French Bulldog is diagnosed with this, let the breeder know as they are passed on from the parents.

### **Oversized eyelid openings and prominent eyes**

The French Bulldog has a very shallow orbit resulting in prominent eyes. This is usually coupled with oversized eyelid openings (macroblepharon). This in turn means that it is more difficult for this breed to blink quickly to prevent trauma. Furthermore it is more difficult for them to distribute the tears evenly over the cornea. This can result in the central cornea drying out. Some French Bulldogs don't quite close down their eyelids when sleeping and this can result in corneal ulceration. If your dog does this, it is suggested that lubricants such as Viscotears, Genteal or even Chlorsig eye ointment are used at bedtime. Surgery is also an option to close down the eyelid opening.



### **Corneal ulceration**

Due to the prominence of the eyes in this breed, trauma resulting in a corneal ulcer is not uncommon. As previously stated, this breed often has low tear production, a slower blink reflex, and a reduced ability to spread the tears over the globe due to their oversized eyelids. All of these factors lead to an increased chance of trauma/corneal ulceration.

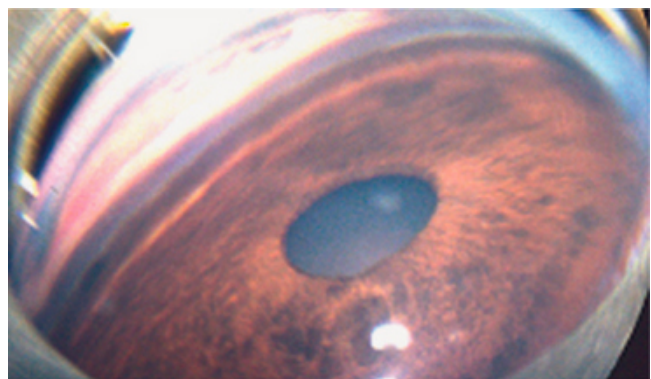
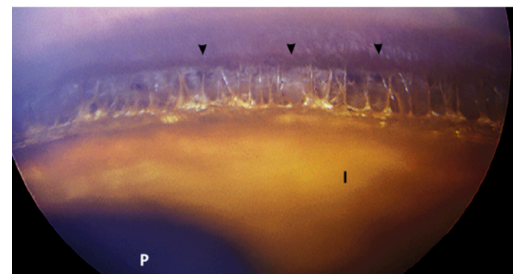
An ulcer is a scratch of the clear surface of the eye - the cornea. A simple ulcer should heal within 5-7 days with simple treatment (ointment and anti-inflammatories). More serious ulcers, including deeper ulcers or those that are infected, require more involved treatment and referral to an eye specialist is recommended. Eye specialists actually suggest that any ulcer in this breed is seen by them as they can progress more rapidly than ulcers in breeds with deep set eyes e.g. Labrador Retriever.

### **Globe Prolapse**

This is another problem related to the fact that French Bulldogs have large eyelid openings, prominent eyes and shallow orbits. Globe prolapse can result from rough play with larger dogs in the park and for this reason, such activity should be avoided. When the globe comes out of the orbit, it should be replaced as soon as possible and the eyelids sutured closed. These sutures should almost completely close the eye and be left in for up to 4 weeks until all the swelling resolves. Complications include permanent outward turning of the globe, scarring and vision loss. We often perform surgery to close down the eyelid openings so that they more closely match the size of the cornea.

### **Primary glaucoma**

Perhaps the most frightening condition that veterinarians and eye specialists are seeing more of in French Bulldogs is glaucoma. This is due to an abnormal drainage angle inside the eye. Fluid (aqueous) is produced and filtered through the drainage angle constantly. If the drainage angle is malformed (goniodysgenesis), the intraocular pressure can suddenly increase (unlike in humans, where the pressure increases slowly over time). This is an inherited condition, passed on from parents with abnormally developed drainage angles. Gonioscopy can be performed to assess a breeding dog's drainage angle and breeding is only recommended in dogs with angles that are over 75% open. Both the percentage open and the width of the angle is assessed.







Unfortunately when glaucoma occurs, the first eye is usually blind and efforts are directed towards delaying glaucoma in the fellow eye (usually prophylactic drops with a drug called Cosopt). Glaucoma is painful and surgery is required - either eye removal or intraocular silicon prosthesis for blind eyes. When glaucoma develops in the fellow eye, surgery is performed to implant a drainage device (Baerveldt Shunt) to try to control the glaucoma. An intensive medication regime is also required. Unfortunately not all surgeries are successful in controlling the glaucoma. This is Lulu who developed glaucoma. She had a prosthesis into the left eye and a shunt right eye. Unfortunately she lost vision in the right eye and required a prosthesis in this eye also.

### **ACES - Australian Canine Eye Scheme**

Eye Certification via ACES is recommended to assess dogs for breeding. This is a full eye examination that will pick up any other eye condition including distichiasis. Only registered veterinary eye specialists who have been listed as ACES Panelists can perform this test. Breeders will be presented a certificate with the full results of the test. Melbourne EyeVet works closely with breeders to ensure that the puppies they bred have optimal eye health. We have worked closely with Golden Retriever, Samoyed and Border Collie breeders in particular to reduce the incidence of glaucoma.



### **Acknowledgements:**

Paintings: Nan Kilgore Little, American artist, judge and dog breeder

Drainage angle photos: open drainage angle Dr Stefano Pizzirani, DACVO;  
closed angle Dr Paul Miller DACVO